

Brain Imaging Correlates

K. Ranga Krishnan, M.B., Ch.B.

Because aggressive behavior occurs in so many psychiatric disorders, it is important to have an understanding of the aggression complex of symptoms, which occurs in posttraumatic stress disorder, bipolar disorder, depression, dementia, schizophrenia, attention-deficit/hyperactivity disorder, and the obsessive-compulsive spectrum of disorders. The effective treatment of aggression symptoms would benefit from the identification of the neuroanatomical circuitry implicated in aggression, and a number of studies in humans and animals using magnetic resonance imaging (MRI) and computed tomography provide evidence that helps identify this circuitry. However, future research still must address several questions. *(J Clin Psychiatry 1999;60[suppl 15]:50–54)*

Aggressive behavior occurs in many psychiatric disorders, including posttraumatic stress disorder, bipolar disorder, depression, dementia, schizophrenia, attention-deficit/hyperactivity disorder, and the obsessive-compulsive spectrum of disorders. The effective treatment of aggression symptoms would benefit from the identification of the neuroanatomical circuitry implicated in aggression, which may be similar in many ways to any other affective regulation. A number of studies in humans and animals using magnetic resonance imaging (MRI) and computed tomography, including single photon emission computed tomography (SPECT), provide evidence that helps identify this circuitry.

NEUROANATOMY OF EMOTION

Hypothalamus

Discussions of the classical brain structures—hippocampus, striatum, frontal lobes, and temporal lobes, among others—often overlook the hypothalamus, but this structure may be critical in the expression of the rage phenomenon. The entire behavioral expression of rage, a subcortical phenomenon, can occur completely without the cortex. Many case reports in human studies have provided evidence for this phenomenon.

Thalamo-Amygdala Circuit

Emotion can be partially explained by separating its component parts, one of which is the sensory component,

the mechanism by which sensory information reaches the critical pieces of the emotional circuit. Sensory information can reach the brain via 2 routes: one through the various cortical association areas and then to the amygdala; another one passes directly from the thalamus to the amygdala. This is the so-called thalamo-amygdala circuit (Figure 1), which is probably the circuit activated when one sees a snake in the grass. The glimpse can be so fleeting that one may not even consciously recognize what has been seen, but the visual experience alone triggers an emotional series of responses, and the speed with which these responses occur precludes multiple processing steps. The information goes directly from thalamus to amygdala.

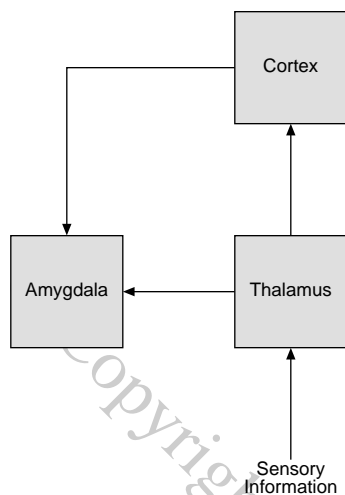
Amygdala

Another part of emotion is the expressive component. A number of studies^{1–3} have indicated that the amygdala is important in assigning emotional significance. With echoplanar functional magnetic resonance imaging, Irwin et al.⁴ reported phasic amygdala activation in normal human subjects reacting to affective stimuli. Removal of the amygdala can produce behavioral responses that are quite dramatic—among them, the loss of ability to process and evaluate emotional information. LaBar and LeDoux⁵ found that unilateral amygdala lesions virtually abolish conditioned fear in rats. Kalynchuk et al.³ reported that rats subject to amygdala kindling explored a novel open field less, avoided the central area of the field more, and resisted capture in the field more compared with sham control rats. Markowitsch et al.⁶ reported on 2 patients, a brother and sister, with damage to the amygdaloid region from Urbach-Wiethe disease. Both patients showed memory impairments on selective tests, and the researchers suggested that the amygdaloid region imparts emotional significance to memories, which makes them more apt to be stored in long-term memory.

From the Duke University Medical Center, Durham, N.C. Presented at the closed symposium "Phenomenology and Treatment of Aggression Across Psychiatric Illnesses," held August 31, 1998, Chicago, Illinois, and sponsored by an unrestricted educational grant from Abbott Laboratories.

Reprint requests to: K. Ranga Krishnan, M.B., Ch.B., Professor and Chair, Department of Psychiatry, Duke University Medical Center, Durham, NC 27706.

Figure 1. Thalamocortico-amygdala and Thalamo-amygdala*



*Adapted from reference 5.

Taylor et al.⁷ noted that the emotional content of stimuli can enhance memory for those stimuli. They speculated that this process could occur either via an interaction with systems governing perception and memory or via the augmentation of specific brain regions specialized for emotions supporting mnemonic processing. The researchers used an 150 positron emission tomography (PET) study to investigate the neuroanatomical systems encoding visual stimuli with strong negative emotional valence compared with stimuli with neutral valence. Participants in the study also performed a recognition memory task for images used as visual stimuli, combined with distracters of similar emotional valence. The test design allowed the researchers independently to test effects of emotional content and recognition memory on regional activity. The authors found activity in the left amygdaloid complex associated with the encoding of emotional stimuli; this activation occurred early in the scanning session and was not detected during recognition memory. Visual recognition memory enlisted the right middle frontal gyrus and the superior anterior cingulate cortex for both negative and neutral stimuli. The lingual gyrus, where greater activation occurred during recognition of negative images compared with recognition of neutral images, was the site of an interaction between emotional content and recognition. The researchers found that emotionally relevant stimuli appeared to enhance processing of early sensory input during visual recognition; there did not appear to be particular neuroanatomical systems for the augmentation of memory with emotion.

Morris et al.¹ have shown that the emotional responses to visual stimuli can be conditioned and that an image seen for less than 40 milliseconds can be masked by a second image shown immediately afterward, in which case a person will react to the original image without having consciously perceived it but will report having seen the sec-

ond image. Morris et al.⁸ found evidence supporting the further hypotheses that (1) the amygdala and certain functionally connected bodies mediate specific neural responses to fearful faces and (2) the early processing of emotional faces can be affected by amygdular activity. The nuclei responding to happy faces may not be exactly the same nuclei that respond to sad faces.

NEUROANATOMY OF AGGRESSION

Basal Ganglia

The basal ganglia circuit, which seems to be critical in motivation and motoric expression, consists of 2 components: a direct circuit and an indirect circuit. The indirect circuit goes to the subthalamic nucleus and may be associated with the agitation response. Removal of the subthalamic nucleus might affect the agitation component. One would expect, to a certain extent, prefrontal, frontal lobe, and striatal damage to produce these kinds of behavioral changes. And interestingly, although the thalamus seems to be an integral part of the circuit, behavioral syndromes that come out of the thalamus have been much more difficult to demarcate. One sees sensory information defects more often than emotional defects.

Amen et al.⁹ conducted a human SPECT study of 40 adolescent and adult men who had shown severe aggressive behavior in the 6 months prior to assessment, physically attacking another person or vandalizing property. Findings from this group were compared with a control group of 40 psychiatric patients in whom such aggressive behavior was absent. Brain SPECT images revealed substantial differences between the study group and the control group, most notably a decrease of activity in the prefrontal cortex, an increase of activity in the anteromedial areas of the frontal lobes, left-sided increased activity in the basal ganglia and/or limbic system compared with the whole brain and decreased activity in the prefrontal cortex, and focal abnormalities in the frontal lobe. The researchers speculate that these findings may attest to a cerebral perfusion profile for patients showing violent or aggressive behavior.

Medial Orbital Prefrontal Cortex

Several neural circuits lead from the amygdala to the prefrontal cortex. Animal data from rat studies suggest that, without the medial orbital prefrontal cortex, social isolation resembling social phobia and avoidance of novelty-seeking behavior result. Another interesting area is the olfactory bulb. The olfactory bulb and the amygdala lead into the medial orbital frontal cortex. We do not know how smell is linked, but the question is interesting.

A particular component of the medial orbital frontal cortex—the 1A region—is very tightly integrated to the amygdala. The medial orbital frontal cortex seems to have an inhibitory affect. Damage to either piece of the circuitry produces reciprocal symptoms. Fibers from the amygdala

connect to the striosomes in the basal ganglia, and the striosomes feed to the substantia nigra. There, a dopamine circuit affects the entire basal ganglia circuit. De Bruin et al.¹⁰ lesioned the orbitofrontal part of the prefrontal cortex in male rats and noted that such rats showed more inter-male aggression than controls.

The medial prefrontal cortex is also very closely linked to the anterior cingulate. The anterior cingulate plays a role in visually recognizing facial emotions and may play a role in aggression. Buchel et al.¹¹ characterized neural responses linked with emotional learning with event-related functional magnetic resonance imaging. Faces were conditioned by pairing with an aversive tone in a classical conditioning paradigm. Comparing responses evoked by conditioned and nonconditioned stimuli, the researchers found differential evoked responses in the anterior cingulate, a body known to have a role in emotional processing. Elliott and Dolan¹² pointed out that our daily behavior depends on a series of hypotheses about the world that are constantly monitored and revised to reflect a changing environment. They conducted a test aimed at identifying the neural foundations of hypothesis testing, particularly in light of the necessity for choice making. Six right-handed volunteers performed an insoluble testing task in which they were asked to designate a rule governing which of 2 stimuli was correct; a control task involved no hypothesis testing. The researchers found activation of the anterior cingulate in hypothesis testing and in choice making.

Hypothalamus

The most common hypothalamic lesion is the craniopharyngioma, and it is not a rare condition. If patients develop aggressive behavior in their twenties and thirties, neurologic causes such as craniopharyngioma should be considered in the absence of other psychological explanations. When craniopharyngioma affects the base of the hypothalamus (the hypophysis), the result can be very severe aggressive behavior. Tonkonogy and Geller¹³ described 2 patients who met DSM-III-R criteria for intermittent explosive disorder. Both patients had craniopharyngiomas that were surgically removed. Instances of rage began before and/or after surgery. MRIs disclosed hypothalamic involvement. The authors suggested a connection in both cases between the hypothalamic lesions and aggression.

Frontal Lobe

Neuropsychological tests can be used to evaluate frontal lobe functioning and its relationship to aggression. Giancola and Zeichner¹⁴ performed a test looking at the conditional association task which, in theory, probably entails the amygdala and reveals defects there appearing to be related to aggressive behaviors. Frontal lobe seizures have classically been related to aggression,¹⁵ and frontal lobe impairment, even in the context of schizophrenia, has been related to aggression.¹⁶

A report from the Vietnam Head Injury Study¹⁷ looked at 279 patients who had received penetrating head wounds during Vietnam duty and 57 controls who were matched for age, education, and length of service in Vietnam. Scales and questionnaires evaluating a spectrum of aggressive and violent attitudes and behaviors were used to collect family observations and self-reports, and 2 aggression/violence scale scores were proposed using observer ratings. Patients with frontal ventromedial lesions consistently registered scores that were substantially higher than those of controls or patients with lesions in other parts of the brain. The researchers speculated that this relationship exists because the human prefrontal cortex stores knowledge that controls primitive reactions to environmental confrontation. Aggression was neither related to seizures nor, interestingly, to the size of the lesions. Location rather than size seems to be important in the development of aggression.

Frontal lobe lesions occur frequently in patients with affective disorder, especially in late life. The term *vascular depression* describes some of the effects in patients who have extensive damage. Very severe aggression and difficulty with impulse control occur often in the context of damage to these regions of the brain. Formal studies are needed to confirm this relationship.

Doudet et al.¹⁸ examined the relationship among cerebrospinal fluid (CSF) 5-hydroxyindoleacetic acid (5-HIAA), aggressive behavior, and cerebral glucose metabolism in 9 rhesus monkeys. The animals, whose CSF 5-HIAA had been sampled over a 2-year period, had a history of aggressive behavior monitored since birth. The researchers found a significant negative correlation between aggressive behavior and CSF 5-HIAA concentrations and between CSF 5-HIAA and regional glucose metabolism in the orbital frontal cortex. The study cohort was very small, and larger studies are called for.

Striatum

The striatum has always been thought to be the motoric component of aggression. Reptile challenge models are being developed to test the effect of stimulating the striatum. Tarr¹⁹ reported electrically stimulating 70 unanesthetized, unrestrained western fence lizards. Resulting behavior included the species' typical assertion display, components of the challenge display—from telencephalic sites—and basic locomotor effects from the brain stem. Twenty-five animals consistently displayed challenge behavior at an average threshold current of 46 microA. Nucleus accumbens and striatum demonstrated the lowest threshold of response and greatest reliability. To our knowledge, there are neither good human nor rhesus monkey studies relating striatal damage to aggression thus far.

Neurovascular System

Vascular depression is very common. Silent strokes are virtually part of growing old. Many silent strokes affect

critical silent—nonmotor, nonsensory—regions of the brain and can lead to various types of emotional problems, from mania to depression. Mania that appears for the first time in persons 50 years old or above almost always involves neurovascular factors. Manic patients in this category develop severe vascular changes, and a significant number of them become demented. The right middle frontal lobe seems to be the locus of depression in late life; the region of the brain involved in mania seems to be bilateral and very extensive.

Hays et al.²⁰ assessed the age at onset, family history, and psychosocial profiles of 74 patients with bipolar disorder. They found less family history of psychiatric problems, more comorbid vascular disease, and more instrumental social support in patients with later age at onset, while patients with earlier age at onset confirmed more stressful life events. The researchers speculated that early onset disorder is characterized by a psychosocial component, while organic factors are implicated in late-onset disorder. Berthier et al.²¹ looked at 9 poststroke patients with bipolar affective disorder. The sole patient reporting a family history of affective disorders was also the only person to have developed symptoms before age 40. The majority of these patients had right hemisphere lesions involving subcortical and midline structures associated with bipolar affective disorder. The authors suggest that subcortical vascular lesions in fronto-basal ganglia-thalamocortical circuits may induce disorders of movement and mood regulation.

Figiel et al.²² and McDonald et al.²³ investigated whether there was a difference in the extent and occurrence of vascular changes between older manic patients who had developed mania when they were young and patients who became manic for the first time when they were older. They found that people who developed bipolar disorder late in life had more extensive changes than those who developed the disorder early in life. In their study of 12 patients in whom the onset of mania had occurred after age 50, McDonald et al. found substantially greater numbers of large subcortical hyperintensities than in control subjects matched for age and sex. Figiel et al. reported deep white matter lesions among 44% of bipolar patients compared to 6% among controls. White matter and subcortical hyperintensities often appear as a tiny dot, a space around the blood vessels probably reflecting atrophy in and around a neighboring region. Others are ductogliosis patterns. Some—mainly seen in the junction between the white and gray matter—are believed to be neurodevelopmental in origin. Often the phenomenon may be vascular. The causes of these changes in younger individuals have not yet been identified.

Hippocampus

Posttraumatic stress disorder (PTSD) is a troubling disorder in which vivid memories of past trauma recur. Van

der Kolk²⁴ noted that normally memory is an active and constructive process. In PTSD, however, he speculated that failure of the declarative memory leads to structuring the trauma on a somatosensory basis that resists change. Intense emotional memories, animal studies suggest, are processed outside the hippocampus. Cortical activity can limit expression of cortically based emotional activity.

There have been many studies of the hippocampus in PTSD patients.^{25–28} Bremner et al.²⁶ used magnetic resonance imaging to compare hippocampal volume in adult survivors of childhood abuse with that of matched controls, finding hippocampal volume 12% less in the abuse survivors. After controlling for alcohol consumption, age, and education, the findings were significant ($p < .05$). Similarly, Gurvits et al.²⁷ used volumetric MRI studies to assess neuroanatomical features of 7 Vietnam veterans compared with 7 combat veterans without PTSD and 8 nonveteran controls. Left and right hippocampal volume were substantially smaller in the patients with PTSD compared with veterans without PTSD and controls; the difference was evident even after adjustments for age, whole brain volume, and lifetime alcohol consumption were made.

Bremner et al.²⁸ conducted a larger study of neuroanatomical changes in patients with combat-related PTSD, comparing 26 PTSD patients with 22 controls similar in factors such as age, sex, race, years of education, socioeconomic status, and alcohol abuse. The researchers found 8% smaller hippocampal volume in the PTSD patients compared with controls, a difference they correlated to deficits in short-term verbal memory as measured using the Wechsler Memory Scale in the PTSD patients. These findings also agree with an earlier study²⁹ by the authors showing short-term memory deficits in patients with combat-related PTSD. The hippocampus is commonly regarded as related to affect, but its relationship to affect is probably indirect.

The amygdala is also important in PTSD. Grillon et al.³⁰ noted that PTSD, with an identifiable etiology and a complex symptomatology, suggested dysfunction in more than a single psychobiological system. They argued that the amygdala is crucial in the encoding and retrieval of fear memories activated by specific stimuli connected with aversive events.

CONCLUSION

Much more research is needed to answer our questions about the neuroanatomical circuitry of aggression. With imaging evidence from animal studies, we can ask whether the emotional circuit for anger is identical to that for sadness or happiness. Are emotions associated with specific component circuits and specific nuclei? We have seen how lesioning or removing certain parts of the brain has affective consequences. Might a patient's inability to extinguish certain behavior be the result of analogous

physical impairment? What if borderline personality disorder is a disorder of the amygdala, one in which the sensitivity of the circuit responds to the emotions in a markedly altered way?

We should also question the direction of current research. Psychiatric studies of imaging presently focus on the cortex, for example, but many of the behaviors discussed here are primarily driven at the subcortical level. The cortical component may be involved in how we describe or feel a behavior, but the actual motoric expression is probably lower. Investigation of the neurologic case report literature will show the relationship of the location of lesions to particular behaviors. The more the neuroanatomical circuitry of aggression is understood, the greater the possibility of successfully treating symptoms found almost universally across psychiatric disorders.

REFERENCES

- Morris JS, Ohman A, Dolan RJ. Conscious and unconscious learning in the human amygdala. *Nature* 1998;393:467–70
- Schneider F, Grodd W, Weiss U, et al. Functional MRI reveals left amygdala activation during emotion. *Psychiatry Res* 1997;76:75–82
- Kalynchuk LE, Pinel JP, Treit D, et al. Changes in emotional behavior produced by long-term amygdala kindling in rats. *Biol Psychiatry* 1997;41:438–451
- Irwin W, Davidson RJ, Lowe MJ, et al. Human amygdala activation detected with echo-planar functional magnetic resonance imaging. *Neuroreport* 1996;7:1765–1769
- LaBar KS, LeDoux JE. Partial disruption of fear conditioning in rats with unilateral amygdala damage: correspondence with unilateral temporal lobectomy in humans. *Behav Neurosci* 1996;110:991–997
- Markowitsch HJ, Calabrese P, Wurker P, et al. The amygdala's contribution to memory—a study on two patients with Urbach-Wiethe disease. *Neuroreport* 1994;5:1349–1352
- Taylor SF, Liberzon I, Fig LM, et al. The effect of emotional content on visual recognition memory: a PET activation study. *Neuroimage* 1998;8:188–197
- Morris JS, Friston KJ, Buchel C, et al. A neuromodulatory role for the human amygdala in processing emotional facial expressions. *Brain* 1998;121(pt 1):47–57
- Amen DG, Stubblefield M, Carmicheal B, et al. Brain SPECT findings and aggressiveness. *Ann Clin Psychiatry* 1996;8:129–137
- de Bruin JP, van Oyen HG, Van de Poll N. Behavioural changes following lesions of the orbital prefrontal cortex in male rats. *Behav Brain Res* 1983;10:209–232
- Buchel C, Morris J, Dolan RJ, et al. Brain systems mediating aversive conditioning: an event-related fMRI study. *Neuron* 1998;20:947–957
- Elliott R, Dolan RJ. Activation of different anterior cingulate foci in association with hypothesis testing and response selection. *Neuroimage* 1998;8:17–29
- Tonkonogy JM, Geller JL. Hypothalamic regions and intermittent explosive disorder. *J Neuropsychiatry Clin Neurosci* 1992; 4:45–50
- Giancola PR, Zeichner A. Neuropsychological performance on tests of frontal-lobe functioning and aggressive behavior in men. *J Abnorm Psychol* 1994; 103:832–835
- Gedye A. Episodic rage and aggression attributed to frontal lobe seizures. *J Ment Defic Res* 1989; 33:369–379
- Cheung P, Schweitzer I, Crowley K, et al. Aggressive behavior in schizophrenia: the role of psychopathology. *Aust N Z J Psychiatry* 1997;31:62–67
- Grafman J, Schwab K, Warden D, et al. Frontal lobe injuries, violence, and aggression: a report of the Vietnam Head Injury Study. *Neurology* 1996; 46:1231–1238
- Doudet D, Hommer D, Higley JD, et al. Cerebral glucose metabolism, CSF 5-HIAA levels, and aggressive behavioral in rhesus monkeys. *Am J Psychiatry* 1995;152:1782–1787.
- Tarr RS. Species typical display behavior following stimulation of the reptilian striatum. *Physiol Behav* 1982;29:615–620
- Hays JC, Krishnan KR, George LK, et al. Age of first onset of bipolar disorder: demographic, family history, and psychosocial correlates. *Depress Anxiety* 1998;7:76–82
- Berthier ML, Kulisevsky J, Gironell A, et al. Poststroke bipolar affective disorder: clinical subtypes, concurrent movement disorders, and anatomical correlates. *J Neuropsychiatry Clin Neurosci* 1996; 8:160–167
- Figiel GS, Krishnan KR, Rao VP, et al. Subcortical hyperintensities on brain magnetic resonance imaging: a comparison of normal and bipolar subjects. *J Neuropsychiatry Clin Neurosci* 1991;3:18–22
- McDonald WM, Krishnan KR, Doraiswamy PM, et al. Occurrence of subcortical hyperintensities in elderly subjects with mania. *Psychiatry Res* 1991;40:211–220
- van der Kolk BA. The body keeps the score: memory and the evolving psychobiology of posttraumatic stress. *Harvard Rev Psychiatry* 1994;1:253–265
- Schuff N, Marmar CR, Weiss DS, et al. Reduced hippocampal volume and n-acetyl aspartate in posttraumatic stress disorder. *Ann NY Acad Sci* 1997; 821:516–520
- Bremner JD, Randall P, Vermetten E, et al. Magnetic resonance imaging-based measurement of hippocampal volume in posttraumatic stress disorder related to childhood physical and sexual abuse: a preliminary report. *Biol Psychiatry* 1997; 41:23–32
- Guryits TV, Shenton ME, Hokama H, et al. Magnetic resonance imaging study of hippocampal volume in chronic, combat-related posttraumatic stress disorder. *Biol Psychiatry* 1996;40:1091–1099
- Bremner JD, Randall P, Scott TM, et al. MRI-based measurement of hippocampal volume in patients with combat-related posttraumatic stress disorder. *Am J Psychiatry* 1995;152:973–981
- Bremner JD, Scott TM, Delaney RC, et al. Deficits in short-term memory in posttraumatic stress disorder. *Am J Psychiatry* 1993;150:1015–1019
- Grillon C, Southwick SM, Charney DS. The psychobiological basis of posttraumatic stress disorder. *Mol Psychiatry* 1996;1:278–297

DISCLOSURE OF OFF-LABEL USAGE

The author of this article has determined that, to the best of his knowledge, no investigational information about pharmaceutical agents has been presented herein that is outside Food and Drug Administration–approved labeling.